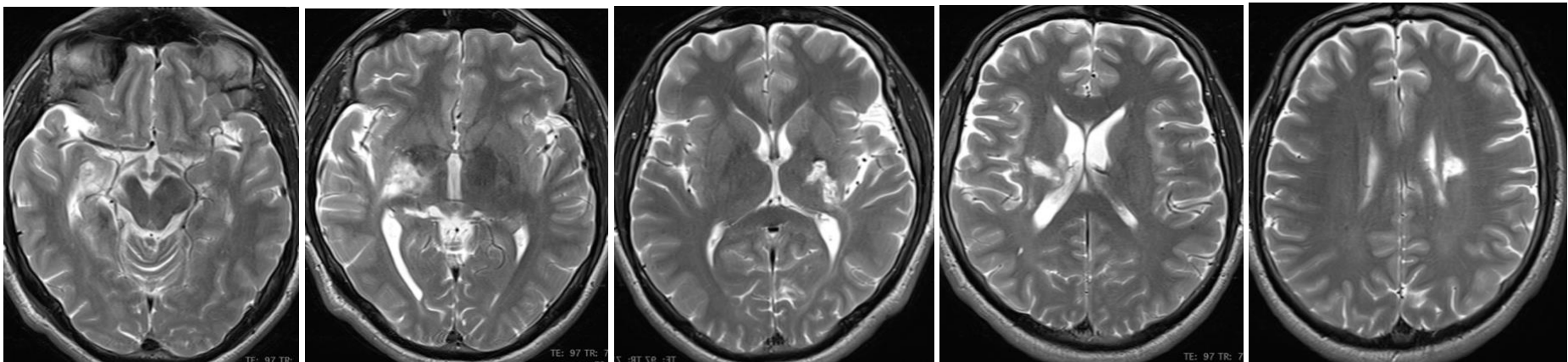


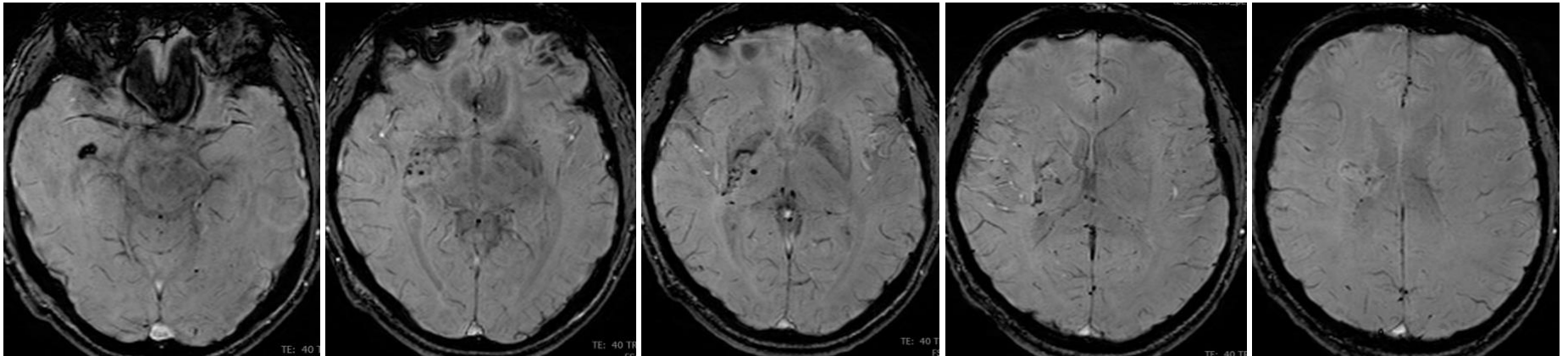
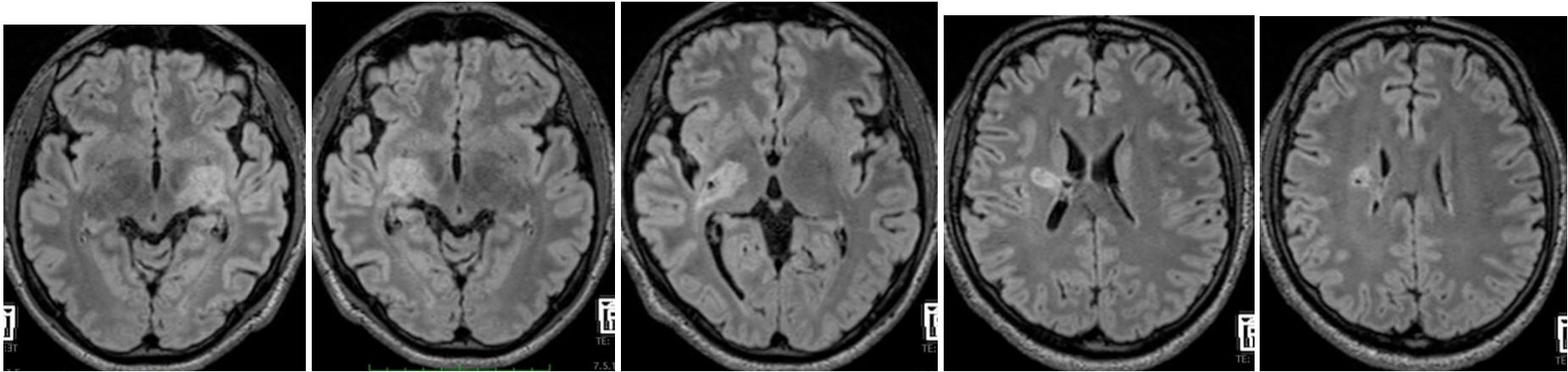
Case Challenge 6-2026

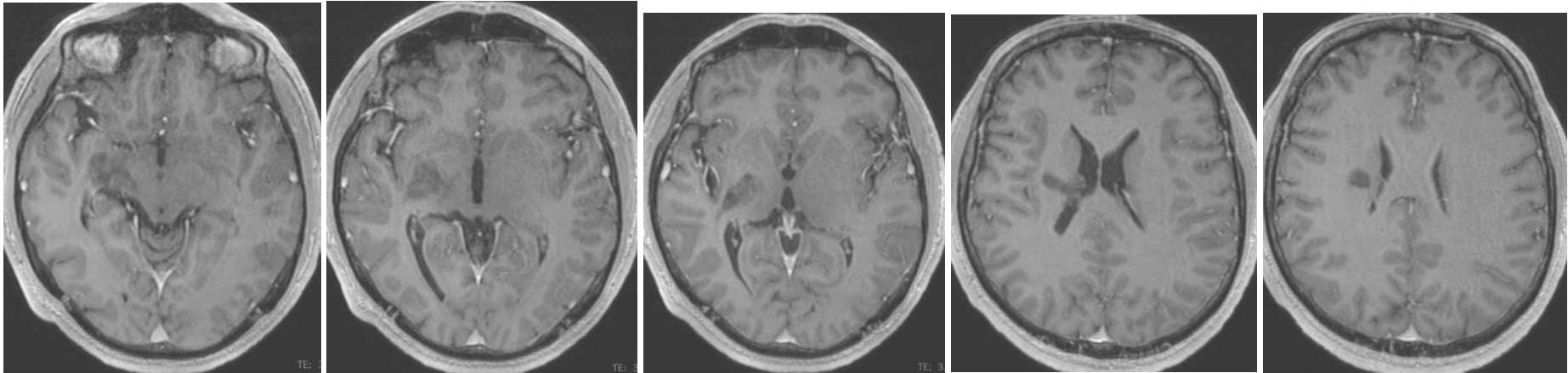
Male, 46 y.o, no specific neurological complains, mostly neurotic behavior. No history of cranial trauma or other conditions.

Neurological examination is normal.

MRI was requested and further examination, cerebral DSA, +- cerebral biopsy accordingly.







What is your opinion?

Answer may be found in previous case lessons reported in our society web page.